

## Pure Cartilaginous Teratoma of the Testis and von Recklinghausen Disease: A Case Report

George Zimmer (1), Peter E. van de Velde (2), Hanspeter Böss (2), Andrea Blöchlinger (2), Claude Gerber (1), Joëlle Tschui (1) and Urs Wagner (1)

(1) Unilabs Pathologie Bern, (2) UroZentrumBeo Spiez, Switzerland

### AIM

Teratomas account for about 7% of testicular germ cell tumors. In adults teratomas usually occur as a component of a mixed germ cell tumor and, uncommonly, as pure (monodermal) teratomas. Although cartilage is a frequent component of testicular teratomas, being found in the majority of cases, monodermal teratomas composed solely of cartilage are exceedingly rare, with only two cases previously described.

### METHODS

We report the clinicopathological, immunohistochemical and molecular (FISH) findings of a testicular tumor that was entirely composed of mature (differentiated) cartilage in a 56-year-old man with von Recklinghausen disease (neurofibromatosis type 1). Interphase cytogenetic analysis was performed by using fluorescence in situ hybridization (FISH) for abnormalities of chromosome 12.

### RESULTS

**Case report:** A 56-years-old man presented with a one year history of a painless lump in his left testis. Blood chemistry showed normal levels for A-FP, B-HCG and LDH. Past history revealed von Recklinghausen disease (neurofibromatosis I) since the age of 14 years with multiple cutaneous neurofibromas. Clinical examination revealed a large mass in his left testis. Clinical and imaging analysis showed a normal contralateral testis and no evidence of metastatic disease. He underwent left orchidectomy. One year after surgery there is no evidence of recurrence.

#### Pathological and molecular findings:

Macroscopically, the specimen showed a 10.5cm, circumscribed, solid, white-gray, rubbery, translucent mass, extensively involving the testis (fig 1). Histologically, the tumor was entirely formed by mature, well differentiated lobulated cartilage (figs 2-3). No extratesticular extension or vascular invasion was found. The remaining testicular parenchyma showed complete tubular atrophy, Leydig cell hyperplasia, and no intratubular germ cell neoplasia or calcifications (fig 6). Immunohistochemically, the tumor was negative for PLAP and CD117, but positive for protein S100 (fig 4). FISH revealed supernumerary chromosome 12, but no chromosome 12p isoforms (fig 5).



Fig 1. Macroscopic view: large, circumscribed, solid, gray-tan tumor occupying the testis.

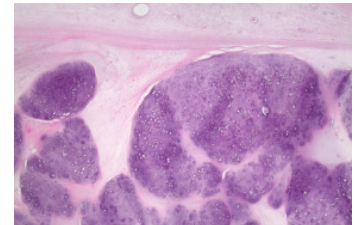


Fig 2. Low power view: lobulated, bluish cartilaginous tumor confined to testis (HE).

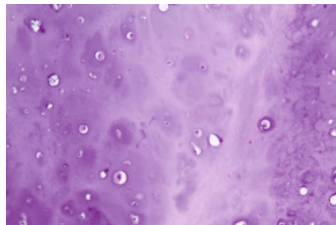


Fig 3. High power view: mature (differentiated) cartilaginous tissue (HE).

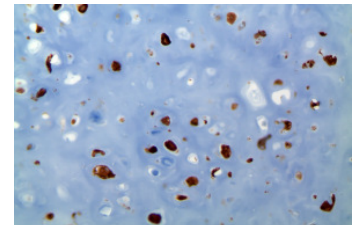


Fig 4. Chondrocytes immunoreactive for protein S100.

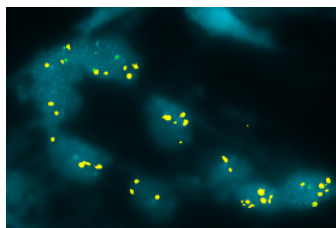


Fig 5: FISH revealing overrepresentation of chromosome 12 (centromere 12 yellow dots, 12p green dots).

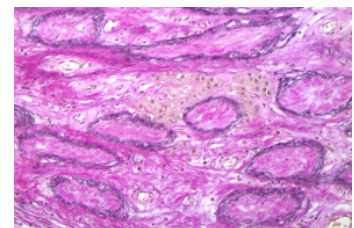


Fig 6: Complete tubular atrophy and interstitial Leydig cell hyperplasia (EVG).

### CONCLUSION

- To our knowledge, this is the first report of a pure cartilaginous testicular teratoma in association with von Recklinghausen disease.
- Overrepresentation of chromosome 12 by FISH was helpful in establishing the tumor's germ cell origin and to disconsider a possible primary testicular chondroma.
- This case supports the observation that an increasing number of different tumors is found in patients with von Recklinghausen disease.
- Postpubertal testicular teratomas, regardless of their appearance, have a definitive risk for metastases, but there are no available data on the management of clinical stage I pure testicular teratomas.

#### References

- Des Jean R, Eble JN, Zhang S, Cheng L. Pure cartilaginous teratoma of the testis: an immunohistochemistry and fluorescence in situ hybridization study. *J Clin Pathol* 2007, 10: 1166-8.
- Singh N, Cumming J, Theaker JM. Pure cartilaginous teratoma differentiated of the testis. *Histopathology* 1997, 30: 373-4.